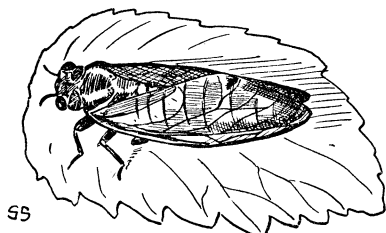


BIOLOGY

NATURE RAMBLINGS

By FRANK THONE



Seventeen Years

In numerous places all over the United States this spring there will be a sudden appearance of hosts of large, brown, clear-winged insects, creeping up the trunks of trees, flying about aimlessly and rather feebly, and then suddenly disappearing again, leaving as a reminder of their visit only a lot of trees with more or less killed-off twigs and withered leaves. It is unfortunate when these happen to be apple or other fruit trees, but this does not often happen.

Oldest inhabitants will say, "Yes, they were here in 1910, and before that in '93, but the worst was the time they came in '76. They're seventeen-year locusts, that's what they are."

To insist on a chilly accuracy, they are cicadas, not locusts; for locusts are grasshoppers. But the seventeen-year part of it is right. The seventeen-year cicada does come every seventeen years—with a few forerunners the year in advance and a few stragglers the year after—and he is the longest-lived insect in the world, so far as we have any knowledge.

The brief life of the insects when they appear is really only their swan-song. Before that they have existed as crawling grub-like creatures for seventeen years underground, feeding on the roots of plants. When their time comes, they emerge, shed their underground clothes, live their few days in the sun, mate and lay their eggs, and thus initiate the cycle over again. The eggs are laid in the tender bark of young twigs, which are killed by the feeding of the newly hatched grubs. Later the larvae drop to the ground and dig themselves in for their long subterranean existence.

Science News-Letter, June 18, 1927

Motion pictures of surgical operations are being made in natural colors in Germany.

ANATOMY

Identify Body With X-Rays

Will the all-penetrating X-ray replace fingerprints as a weapon for tracking down criminals? A spectacular case, the first on record, in which the identification of a person has been obtained through the use of X-ray photographs is described in a report just made to the American Medical Association by Drs. William Ledlie Culbert and Frederick M. Law, of New York City.

In January, 1920, Dr. Culbert operated on a man, designated as J. L., for mastoiditis on the left side, a procedure that relieved chronic headache. As is usual in such cases several X-ray studies were made of the face and head.

"In 1925 this patient," said Dr. Culbert in his report, "went to India and wrote to his family of his intention of going into Thibet; as entry was forbidden by the Indian government, he stated that it would be necessary for him to 'disappear'; i. e., to drop officially out of sight. In the meantime he gathered his caravan together and encamped temporarily with some friends on the banks of the Indus River in Kashmir. June 8, 1925, great alarm was occasioned by his sudden disappearance, and search was started along the river. Seventeen days later, the bodies, first of one white man, and then of another, both badly dismembered and disfigured beyond any possibility of recognition, were found in the river, 70 miles below camp. We were appealed to by the family for possible means of identification and suggested the scar of a simple mastoid operation on the left side."

One of the bodies showed such a scar and was shipped to New York. J. L. was heir to much real estate to which title could not be given without positive identification, which was made increasingly necessary because of the written statement of J. L. to his family of his intention to disappear into Thibet. The body was terribly disfigured.

"On being asked if we could furnish means of more positive identification, we replied unhesitatingly that we could do so, for we still held in our possession roentgenograms of the nasal accessory sinuses and of both mastoid bones of J. L., taken in 1918. We had noted in many other cases the absolute identity of roentgen-ray pictures taken of these structures, in the same patient, after lapses of five, ten, fifteen or more years. Although we

had never before had occasion to use the fact, as shown by roentgenograms, of the unchanging shape, size, contour and relation to neighboring structures of the pneumatic cells of the skull as a means of personal identification, these facts could unquestionably so be used."

The second set of X-ray pictures established conclusively the identity of the slain man. In both sets the nose wall of the orbit of the eye was curved more on the right than the left and the upper curve of the right eye-socket was slightly flattened in both pictures. Various other formations of the bones of the face were found to correspond. The identification was further confirmed by the recognition of the three gold inlays in the teeth of the body by the dentist who had attended J. L. in 1924 and 1925.

The whole subject of roentgenography of the head as means of identification for criminals has barely been touched, the doctors believe. It offers advantages over fingerprinting in that finger tips can be intentionally mutilated and for some reason the head seems to be preserved more often than the hands in many of the more gruesome murder cases. Any amount of deforming surgery, moreover, cannot destroy the identifying landmarks of the skull bones.

Science News-Letter, June 18, 1927

ASTRONOMY

Australian Discovers Comet

A new comet of the eighth magnitude, too faint to be seen with the unaided eye, but bright enough to be observed with a small telescope, was discovered on June 7 by Walter F. Gale, a Justice of the Peace of Sydney, Australia, who spends his spare time observing stars. This is according to reports reaching the Harvard College Observatory, it was announced by Dr. Harlow Shapley, director of the observatory. However, stated Dr. Shapley, the discovery has not yet been confirmed.

According to the report, the comet was in the constellation of Piscis Australis, the southern fish, a star group that is seen low in the southern sky now about 3.30 a. m. However, in Australia, this constellation would be nearly overhead.

Its position, as astronomically expressed, was then 21 hours and 38 minutes in right ascension and 31 degrees 38 minutes in south declination.

Science News-Letter, June 18, 1927