

## Color Test for Vitamin

*Physiological Chemistry*

The color test for vitamin A in cod liver oil has now been proved thoroughly reliable when compared with the old biological method of testing for presence of this vitamin, according to experiments carried on at laboratories in the University of Sheffield, University College, London, Kings' College for Women, London, The Lister Institute and the University of Oslo.

At these laboratories several different samples of the oil were tested by the biological method, which is a feeding method carried out on experimental animals, and the same oils were tested by the color test by Dr. Otto Rosenheim, of the National Institute for Medical Research, who originally devised the color test. The results were so similar that the reliability of the color test was proved without any doubt.

However, the two methods are now to be compared for other substances containing vitamin A, such as butter.

*Science News-Letter, July 28, 1928*

## X-ray Pictures of Brain

*Anatomy*

A method of investigating the brain by means of X-ray photographs has been perfected by Dr. Max Ludin, director of the Roentgen Institute of the Citizens' Hospital, Basel, Switzerland. Making use of the contrast method generally used in X-ray diagnoses of other conditions, Dr. Ludin has been able to locate exactly tumors in the brain, thus making removal of the tumor by operation much easier.

Air is pumped into the cavities of the brain where it shows as white patches in the X-ray pictures. If one of the cavities contains a tumor, the air cannot penetrate into the cavity and so the white patch does not show.

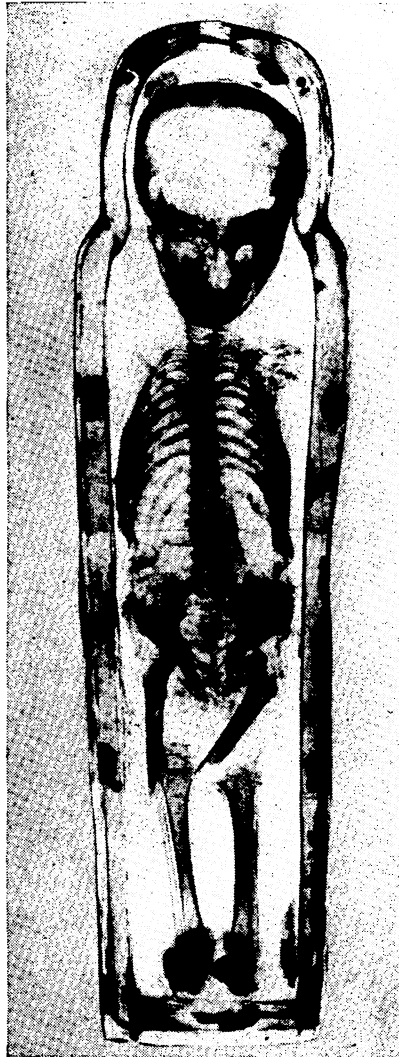
In making X-ray pictures of the medulla, which is the part between the spinal cord and the brain, a specially prepared oil is used instead of air. This oil is heavier than the spinal fluid which fills the medullary canal, so it flows down, appearing in the picture as a black strip. If there is a tumor in the canal, the strip stops at the upper edge of the tumor.

Dr. Ludin is now working with an oil lighter than spinal fluid, by which he hopes to find the lower edge of the tumor, thus locating it exactly for operation.

*Science News-Letter, July 28, 1928*

## X-Rayed Mummies Show Broken Bones

*Archæology—Pathology*



*X-RAY PHOTOGRAPH of mummified child, showing how leg bones were broken to make the body fit the mummy case*

The theory that ancient Egyptians were intensely sincere worshipers of their dead is challenged by X-ray studies of mummies now being carried on at the Chicago Field Museum by Miss Anna R. Bolan, staff roentgenologist.

Specimens thus far studied reveal that, while the outside wrappings were always elaborate, the bodies inside were not always so carefully treated. One mummy case contained only a skull and legs with a few finger bones carelessly thrown in. Another picture, reproduced herewith, was that of a small child, and showed that both arms had been severed and the upper bones of both legs broken to make the body fit into the case. A long animal bone was discovered inside the body of a female mummy,

indicating that embalmers were sometimes careless in their work.

Pathological studies were made by Dr. Cora A. Matthews of the staff of Cook County Hospital, a noted diagnostician. In the X-ray pictures of three mummies of Egyptian children she found traces of diseases common among children of today. The X-ray pictures show two of these mummified children had a distinct scoliosis or curvature of the spine, Dr. Matthews reports, a condition due to incorrect sitting posture. This is often found among school children today, and teachers and public school health authorities are continually at work to prevent its spread.

The other mummified child, a small baby, was a victim of malnutrition, Dr. Matthews says, as the X-ray pictures show transverse lines of irregular calcium development in the bones, the condition which is caused by improper and inadequate feeding among many children of poor families today.

Photos were made with the X-ray apparatus recently presented to the museum by its president, Stanley Field. The introduction of the X-ray is a new departure in museum practice, and the Field Museum is the first institution of its kind in the world to adopt it. It is believed still to be the only museum so equipped. The apparatus is used not only on mummies, but makes it possible to inspect the inside of many kinds of anthropological, botanical, geological and zoological specimens, and establish many scientific facts without damage to the specimens.

The X-ray pictures of mummies will remain as a permanent exhibit in Egyptian Hall, along with the mummies which they represent. There are a number of others, besides those of the three children, on display. A noted palæopathologist, Dr. Roy L. Moodie, formerly of the University of Illinois, is making further pathological studies of others by the X-ray photographs.

*Science News-Letter, July 28, 1928*

There are more Canadians in prison for serious crimes in the United States than in Canada.

Ancient desert caravans of Mediterranean countries are rapidly being replaced by trans-desert automobile services.