

First View of Chiron's Farthest Fringes

In 1977, when astronomer Charles Kowal discovered the object now called Chiron circling the sun between the orbits of Saturn and Uranus, he could not tell whether it was a comet or an asteroid. The first evidence for Chiron as a comet did not appear until late 1987, as the rocky object's orbit carried it closer to the sun. Measurements showed it brightening more rapidly than would a mere asteroid — which is just what the icy nucleus of a comet ought to do as the sun's heat vaporizes the ice and releases it as a diffuse but growing cloud, or coma, surrounding the comet's head.

Now, Jane X. Luu of MIT and David Jewitt of the University of Hawaii at Manoa have taken what they say is "believed to be the deepest (most revealing) image of this object [Chiron] ever recorded."

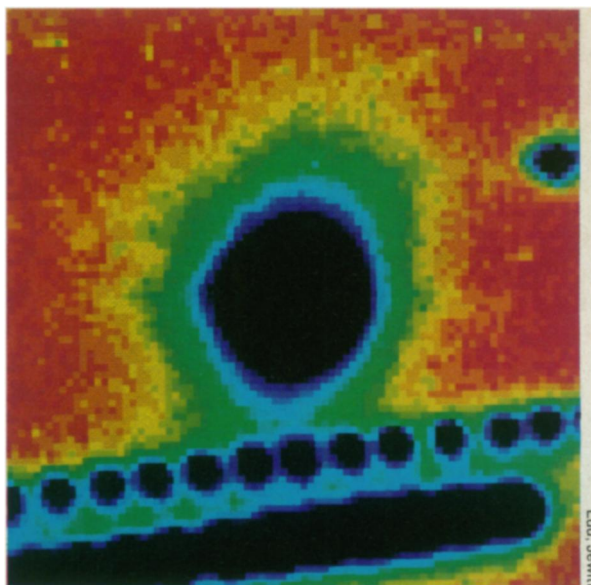
They made the image on Jan. 29, using the University of Hawaii's 2.24-meter telescope on Mauna Kea. The researchers combined 40 separate exposures, each 500 seconds long and taken one after another, that essentially add up to a single time exposure lasting more than 5.5 hours. The cumulative exposures allowed a computer to integrate enough light to reveal even the faint outer fringes of the coma. The resulting composite shows the coma, as seen from Earth, extending about 80,000 kilometers from

Chiron's center to each side, while single exposures show only the inner 36,000 km to each side, Luu and Jewitt say.

Jewitt points out, however, that the coma is actually "a highly elongated structure almost parallel to the line of sight from Earth, preventing us from seeing its full length." Its true length is 2 million km, he told SCIENCE NEWS.

Chiron's brightness increased steadily through 1988. The comet reached its maximum brightness — about twice that of an asteroid — in December 1988, and has faded ever since. Astronomers made their first direct observations of the coma itself about a year ago, having only measured changes in Chiron's overall brightness before that time.

One reason the brightness increase has reversed, Jewett says, could be that Chiron's nucleus contained pockets of material that turned to gas and burst forth when heated by the sun, and the amount of released material diminished over time. Candidates for these now-exhausted materials include carbon monoxide, carbon



In this 5.5-hour composite image of Chiron's coma, repeated images of a star appear as a row of spots, showing the successive exposures combined to increase the coma's brightness.

dioxide and nitrogen, he suggests. Another possible coma-forming candidate might be "amorphous ice" in the nucleus, which could give off heat as it crystallized, but Jewitt suspects that any water released would freeze rather than evaporate to form a coma. — J. Eberhart

Treatment may reduce post-stroke damage

A ballooning weak spot on an artery wall bursts suddenly, spilling blood into the fluid surrounding the brain. This catastrophic event, a form of stroke called subarachnoid hemorrhage, strikes an estimated 35,000 people in the United States each year.

Physicians treating people who survive the initial vessel blowout face a grim dilemma. On the one hand, early surgery to clip or repair the vessel wall can lower the patient's chance of a second deadly bleed should the weak spot burst again. But some researchers have suggested that people recovering from such surgery run an increased risk of another setback: Intact arteries supplying blood to the brain may constrict, robbing brain cells of blood and threatening neurological problems such as paralysis, speech difficulty or permanent brain damage.

On the other hand, delaying surgery until vessel constriction subsides exposes the patient to the threat of a second, potentially fatal artery rupture.

In a preliminary study, British re-

searchers have now found that an experimental drug — calcitonin-gene-related peptide — temporarily reversed symptoms caused by reduced blood flow to the brain in people recovering from surgery for a ruptured artery. If larger studies confirm these results, the treatment might make early surgery safer for people who have suffered subarachnoid hemorrhage, suggest F.G. Johnston of the Atkinson Morley's Hospital in London and colleagues in the April 14 LANCET.

Johnston's group studied 15 patients who had just undergone early surgery for subarachnoid hemorrhage and who showed neurological symptoms indicating reduced blood flow to the brain. They gave each patient one infusion of calcitonin-gene-related peptide and one infusion of a placebo solution, in random order, 24 hours apart. Nine of the 15 showed improvement after receiving the drug, while only two of the 15 improved after placebo shots, the researchers report. These results suggest the peptide can reverse ongoing vessel

spasm, they say.

The symptomatic improvement noted by the British researchers lasted only 15 to 50 minutes after the drug infusion ended. Scientists still don't know whether continuous infusion during the risky postsurgical period — perhaps for as long as two weeks — would prevent neurological damage over the long run. Vessel spasms in patients recovering from surgery usually persist for a limited period and then subside, Johnston told SCIENCE NEWS.

Neal F. Kassell, a neurosurgeon at the University of Virginia School of Medicine in Charlottesville, calls calcitonin-gene-related peptide a "potential new treatment for vasospasm." However, he and neurologist Harold P. Adams Jr. emphasize the preliminary nature of the new report. "Fifteen patients is far from a conclusive study," says Adams, of the University of Iowa College of Medicine in Iowa City. "What is needed now is a much more extensive experience with this therapy to learn where it fits in with the management of patients with subarachnoid hemorrhage."

— K.A. Fackelmann