

Astronomy

Ron Cowen reports from College Park, Md., at the annual University of Maryland astrophysics conference

A matter of gravity

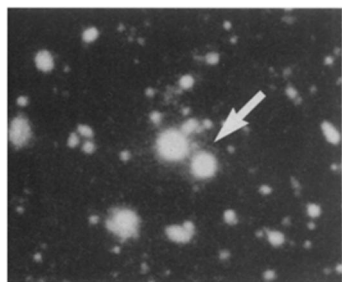
Will the universe expand forever or eventually collapse? The answer wouldn't seem to depend on the detailed appearance of an individual quasar system. But astronomers say the true nature of a double quasar may shed light on the question.

The double quasar Q2345+007 has intrigued scientists since its 1982 discovery. Debate continues about whether these twin beacons of light are two distinct quasars with similar spectra and locations or a cosmic mirage that originates from a single quasar. In the latter case, a massive object in front of the quasar would act as a gravitational lens, splitting or distorting the single beacon's light into two images.

Previous searchers for a cluster of galaxies that would constitute the lens came up empty-handed. But now astronomers using data from three telescopes have examined the double quasar and its surroundings with a sensitivity unmatched by surveys anywhere else in the sky. They report that they have found several massive candidates for the gravitational lens. If

their circumstantial evidence proves correct, it suggests that massive, compact clumps of matter existed earlier in the universe than several cosmological models can easily explain.

The team of astronomers gathered some 22 hours of observations from telescopes in Hawaii, Chile, and Arizona. They say two findings support



Flickr/Wenk

Image of the double quasar Q2345+007 (arrow).

the notion that one or more clusters of galaxies act as a gravitational lens for the quasar.

Philippe Fischer and J. Anthony Tyson of AT&T Bell Labs in Murray Hill, N.J., and their colleagues found a higher than average density of faint galaxies in the vicinity of Q2345+007. They also detected an individual faint galaxy that lies near one of the two quasar images.

This galaxy may be responsible for the absorption of a narrow band of wavelengths in the spectra of the double quasar. If so, the galaxy would have to reside an estimated 9 billion light-years from Earth and would have formed when the cosmos was less than 40 percent of its current age. And if it is indeed part of a gravitational lens, the galaxy would belong to a cluster containing as much mass as 10 trillion suns.

But there's a cosmological rub. Several models for the universe's evolution can't explain massive clusters forming only a few billion years after the Big Bang. "It takes a long time to accumulate this much matter into so small a region," Fischer says.

In one popular cosmological model, the universe contains just enough matter that mutual gravitational attraction will eventually halt the expansion of the universe. The cosmos would teeter between an open universe, in which the expansion continues forever, and a closed universe, in which complete collapse is inevitable.

In this model, much of the unseen, or dark, matter that astronomers believe makes up most of the mass of the universe would take the form of exotic material rather than ordinary atoms. But even hypothetical material known as cold dark matter, which moves more slowly and clumps more easily than other exotic types, couldn't explain such early formation of galaxy clusters.

Instead, concludes the team, an open universe in which ordinary neutrons and protons make up most of the dark matter may best account for the team's preliminary findings.

Behavior

Imaging clues to schizophrenia

Schizophrenia unhinges mental life with an array of tools that includes hallucinations and delusions, incoherent trains of thought, inappropriate or blunted emotions, and a deep-seated sense of apathy. The search for schizophrenia's roots has yet to yield any clear-cut cerebral culprits.

However, a study in the Oct. 14 *SCIENCE* suggests that this debilitating condition may spring from abnormalities in the thalamus and areas throughout the brain with anatomical links to that structure. Prior evidence suggests that the thalamus — located deep within the brain — helps to focus attention, filter sensations, and process other types of information.

Troubles in the thalamus and its related structures, which extend from above the spinal cord to behind the forehead, can create the full range of symptoms observed in schizophrenia, suggest psychiatrist Nancy C. Andreasen and her colleagues at the University of Iowa Hospitals and Clinics in Iowa City.

Andreasen's team took magnetic resonance imaging (MRI) scans of the brains of 47 healthy men and 39 men diagnosed with schizophrenia. They then transformed each brain image onto the same three-dimensional space. The average intensity of the magnetic signal in each unit of those images was computed for men in the two groups, yielding an average schizophrenic brain and an average healthy brain.

Then the team subtracted the average schizophrenic brain from its healthy counterpart to identify areas in which the two differed most. The greatest contrast in signal strength emerged for the thalamus and adjacent tissue that lead to the front of the cortex. Schizophrenic men also displayed a substantially smaller thalamus than the comparison men.

Most abnormalities appeared in the brain's right hemisphere, a finding that contrasts with many previous studies that have emphasized left-hemisphere problems in schizophrenia.

Impairment of the brain circuitry that runs through the thalamus; which perhaps occurs before or shortly after birth, may represent a "core disturbance" that underlies the various manifestations of schizophrenia, Andreasen proposes.

However, it remains unclear whether the deficits noted in her study apply only to schizophrenia or to other severe psychiatric disorders as well. Researchers must also clarify whether these abnormalities primarily cause schizophrenia or result from years of antipsychotic drug use.

"This new study is a novel, interesting approach, but what it means about brain pathology in schizophrenia is difficult to interpret," asserts Daniel R. Weinberger, a psychiatrist at the National Institute of Mental Health in Bethesda, Md.

For example, the implication of differences in MRI-produced images for actual brain function remains unknown, Weinberger holds. Andreasen's group also replicated prior findings that schizophrenic men have smaller brains with larger fluid-filled spaces, a trait that may play a greater role in this condition than thalamic abnormalities, he adds.

Brain gets thoughtful reappraisal

Two brain regions often associated solely with the control of muscle movement also help coordinate thinking, according to a report in the Oct. 21 *SCIENCE*. This supports the view of some researchers that malfunctions in these structures, the basal ganglia and the cerebellum, contribute to schizophrenia.

Frank A. Middleton and Peter L. Strick, both neuroscientists at the State University of New York Health Science Center in Syracuse, injected a live strain of the herpes simplex virus into three monkeys at a forebrain site known to be involved in planning the order and timing of future behaviors. Five days later, the virus had moved through nerve connections to the basal ganglia and cerebellum at the back of the brain, indicating their involvement with the forebrain location.