

MEDICINE

Eye Cancer Can Be Cured

Retinoblastoma, a disfiguring and sometimes fatal disease of the eye, can be cured in the great majority of cases which are discovered early—By Faye Marley

► THE MALIGNANT TUMOR of the retina called retinoblastoma can now be cured in 85% to 90% of cases that are discovered early and treated by combinations of X-ray and drugs.

Dr. Richard B. Lyons, a geneticist at the University of Oregon, told SCIENCE SERVICE at an ophthalmology seminar that the prospects for treating this tumor, which mainly affects babies and children, have improved greatly during the past 20 years.

The untreated tumor eventually brings about a protrusion of the globe of the eye, with a resulting "pitiful as well as inescapable" appearance. Fortunately it is a rare disease, occurring only in one out of 14,000 live births.

Dr. Lyons and his team found an abnormal chromosome in cells from a one-year-old boy who later died of retinoblastoma. The geneticist warned, however, that this does not mean that the abnormality is present in all patients who have the tumor.

What he found was that a chromosome of the D group, one of seven groupings based on size and shape, was missing and was replaced by a much smaller fragment that was probably the remnant left after breakage or deletion of the original D chromosome.

A similar finding had been reported in London in one of six patients at the Galton Laboratory.

Dr. Lyons' patient was born with numerous congenital abnormalities, including small eyes and a keyhole-shaped defect in

the iris, which caused the physician to make chromosome studies when the boy was just a year old.

A speaker at the same eye seminar in Arlington, Va., was Dr. A. B. Reese of Columbia University, New York, who went so far as to advise a female survivor of such an affliction to have an abortion or be sterilized. Dr. Reese has worked on the problem for 20 years. He said retinoblastoma occupies a unique position as the only truly malignant human tumor with definite hereditary characteristics, which he said are due to an autosomal dominant gene.

• Science News Letter, 88:327 November 20, 1965

MEDICINE

Red Eyes May Mask Dangerous Glaucoma

► RED EYES MAY MASK dangerous glaucoma or acute uveitis, which means inflammation of the uvea, the part of the eye containing the iris and blood vessels. Red eyes can often be safely treated by the family doctor, but he must be sure of the diagnosis, an ophthalmologist warns.

Conjunctivitis probably can be treated by the practicing physician, but both uveitis and glaucoma cases should be treated by an eye specialist. Whether or not a person should be referred to an ophthalmologist is a decision requiring great care by the family doctor.

A doctor should not put a patch on the

eye of a patient found to have acute conjunctivitis, as the patch will make the bacteria flourish more and can cause infection in the cornea.

Dark glasses, however, may be worn after drops or ointment are used as treatment. An antibiotic that is not ordinarily used "systemically" is advised, such as neomycin, bacitracin and polymyxin B, after a bacteriological study is first made.

Dr. Ellis Gruber, clinical instructor in ophthalmology, University of Rochester, Rochester, N.Y., reported in Medical Times, Nov. 1965, details of diagnosis and treatment of various eye diseases that can be hidden by red-eye symptoms.

"Subconjunctival hemorrhages are one of the commonest causes of red eyes," he said, adding that although they are often the most alarming to a patient, they usually clear up in about two weeks without special treatment. Cold compresses may be applied at first to prevent further bleeding, followed by hot compresses after two days to help the blood be absorbed.

These harmless hemorrhages often follow sneezing, coughing, rubbing the eyes, or they may occur spontaneously in a person who has hardening of the arteries.

Keratitis, which means inflammation of the cornea, often causes a red eye by producing a secondary conjunctivitis. The normal clear corneal surface may look irregular in the area, and the light reflexes from it are irregular. Such cases should be referred to an ophthalmologist for an adequate slit lamp examination.

Antibiotics and antibiotic-steroid combinations are used in treatment.

An uncommon cause of red eyes is episcleritis, which means inflammation of the sclera and the tissue between it and the conjunctiva.

Scleritis, inflammation of the white of the eye, is another uncommon cause of red eyes. Both these conditions require treatment by an ophthalmologist.

• Science News Letter, 88:327 November 20, 1965

MEDICINE

Whooping Cough Vaccine Advised at Three Weeks

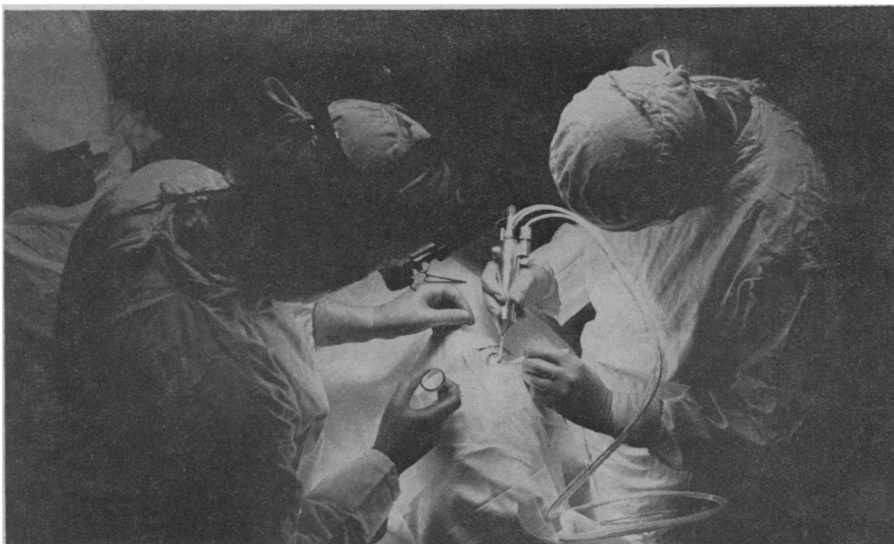
► NEWBORN BABIES probably should not be immunized against whooping cough before they are three weeks old, a group of Massachusetts physicians said.

If the injections were started within 24 hours of birth the doctors found that whooping cough, or pertussis, immunization does not produce the desired protection. This is true whether the injections contain only pertussis vaccine, or are a combination of diphtheria, tetanus and pertussis vaccines.

A group of babies were given the first of the series of injections within 24 hours after birth to test the reaction. The present report, on pertussis, will be followed by succeeding reports on diphtheria and tetanus antibody responses.

Drs. R. William Provenzano, Leslie H. Wetterlow and Charles L. Sullivan reported in The New England Journal of Medicine, 273:959, 1965.

• Science News Letter, 88:327 November 20, 1965



Research to Prevent Blindness, Inc.

SURGICAL FREEZING TECHNIQUE—Cryosurgery, which replaces the scalpel with a freezing procedure, is being performed here in an operation on the eye, although it is not widely used in this way. Traditional surgery is usually employed in cataract removal but rapid freezing and other methods are growing in popularity.